

CASE REPORT / PRESENTACIÓN DE CASO



Cerebral edema during the management of diabetic ketoacidosis in an adult with new onset diabetes mellitus

Edema cerebral durante el tratamiento de la cetoacidosis diabética en un adulto con diabetes mellitus de debut

Alexei Ortiz Milan¹, Megan Cox¹, Carlos Medina Mirino², Aurelio Rodriguez Fernandez¹, Yordanka Pina Rivera³

Abstract

Cerebral edema associated with Diabetes Ketoacidosis (DKA) is a rare but frequently fatal complication typically occurring 4 to 12 hours after initiation of treatment, but it can develop any time during DKA management. Some risk factors for DKA-related cerebral edema have been identified. Diagnosis of this lethal condition is based in clinical grounds, mainly by deterioration of the level of consciousness and CT-brain appearance. Treatment should be focussed on prevention by minimizing all the known risk factors.

Key words: Cerebral edema; Diabetes ketoacidosis; Management

Resumen

El edema cerebral asociado con cetoacidosis diabética (CAD) es una compli-

cación rara pero con frecuencia mortal que ocurre típicamente entre 4 a 12 horas después del inicio del cuadro, pero algunas veces puede desarrollarse durante el tratamiento de la CAD. Se han identificado algunos factores de riesgo para la aparición del edema cerebral relacionado con la CAD. El diagnóstico de esta letal complicación se basa en manifestaciones clínicas, principalmente deterioro del nivel de conciencia, y por TAC de cráneo. El tratamiento debe ser enfocado en su prevención minimizando todos los factores de riesgo conocidos.

Palabras clave: edema cerebral; cetoacidosis diabética; manejo

Introduction

Cerebral edema developed during the treatment of Diabetes ketoacidosis (DKA) is a severe and unpredictable complication which pathological findings were initially described in adult in 1936 and first recognized in children in 1960.^{1,2} Clinically apparent cerebral edema occurred in 61 of 6977 hospita-

lizations for diabetic ketoacidosis during the study period (0.9 percent; 95 percent confidence interval, 0.7 to 1.1 percent). Cerebral edema is an extremely rare complication of DKA treatment in adults.^{3,4} In children an incident of 0.3 to 1% has been reported and it is responsible for 50 to 60% of diabetic-

related deaths.^{3,5} An experimental study in animal model has showed that rapid correction of hyperglycemia and hyperosmolality resulted in a significant increase in brain water content.⁶ We presented a young adult patient who is

admitted to ICU in our facility with the diagnosis of DKA whom developed cerebral edema documented by CT-Brain during the course of the management.

Case study

A 28 year old HIV negative male with a history of recurrent sexually transmitted diseases presented to small hospital within 100km of Gaborone with one week history of fever, nausea, vomiting, and generalized body aches. The doctor's assessment stated the patient initially looked sick, but he was communicative. The patient was noted soon after presentation to become non-communicative and hypotensive, with random blood glucose (RBG) of 31.3 mmol/L and a urine dipstick analysis revealing ketones 1+. Two large bore intravenous lines were inserted and 4 litres of intravenous normal saline and 20 IU of actrapid insulin administered. The RBG was monitored every 20 minutes and 20 IU of actrapid insulin was repeatedly given to the patient up to 80 IU in total.

The patient was transferred to the Emergency Department at our referral hospital and reassessed. On arrival the vital signs were unstable with hypoten-

sion (BP 96/45 mmHg), tachypnea (RR 32/min), hypothermia (T 34.60°C), but oxygen saturation of 100% on 15 litres mask oxygen, and RBG of 21.8 mmol/L. The physical examination revealed generalised pallor, crackles in right lung base, a petechial rash on the chest, and Glasgow Coma Scale (GCS) of 9 points. Arterial blood gases showed severe metabolic acidosis (pH 6.88, PCO₂ 13 mmHg, PO₂ 119 mmHg, HCO₃ 2.9 mmol/L). A rapid malaria test was requested as there was a history of travel to an endemic area of malaria but the result was negative. A full septic work up was obtained including a lumbar puncture which was also negative. An abdominal ultrasound was performed at the bedside showing small amount of free fluid in the abdomen. The patient was intubated and a Head and Abdominal CT performed (Figure 1), neither of which revealed any remarkable findings.

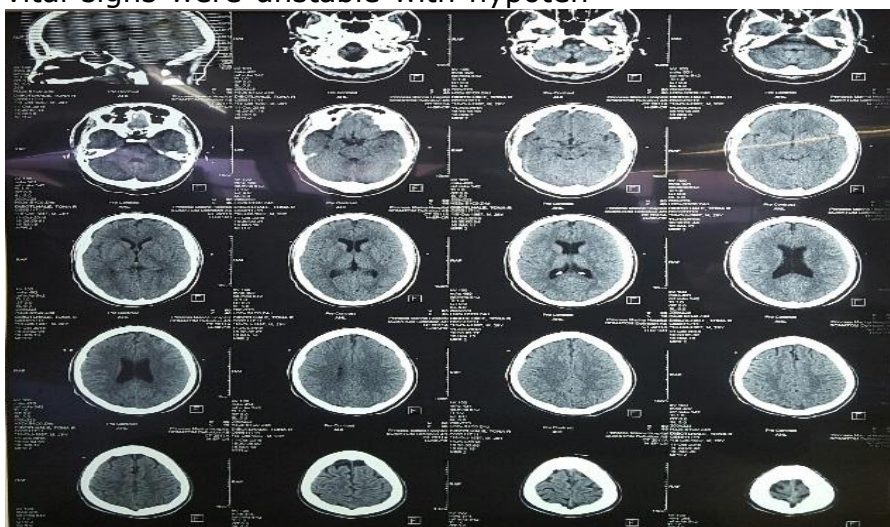


Figure 1: Head computed tomography before ICU admission

The patient was subsequently admitted to our ICU and placed on volume assist/control mode ventilatory support and displayed persistent hemodynamic instability, with a diagnosis of diabetes ketoacidosis and septic shock.

Resuscitation continued with intravenous 0.45% normal saline at 500 ml/h, Actrapid infusion at 0.1 IU/Kg/h, broad spectrum antibiotics (Cefotaxime 2 g iv 8 hourly + Clindamycin 600 mg iv 8 hourly + Doxycycline 100 mg per nasogastric tube twice a day).

The patient required initiation of vasopressors noradrenaline started at 0.02 µg/kg/min and titrate upward until hemodynamically stability achieved at 0.1 µg/kg/min. Repeat urine dipstick on ICU admission was ketones 2+, blood glucose (BG) 4+, and protein 2+. Once good urine output and normal serum potassium level were documented, potassium was added to the maintenance intravenous fluids. Twenty four hours after admission the patient still had a significant metabolic acidosis. Table 1 shows the laboratory investigations from the ICU admission. Forty eight hours after admission the patient still required mechanical ventilation,

vasopressor infusion and intravenous sodium bicarbonate 8%. On day three in ICU, sedation was ceased but the GCS was 3 points. A CT-Head was repeated at this time, looking for cerebral edema, which was confirmed (Figure 2).

The following day the patient was still mechanically ventilated but an improved level of consciousness with GCS of 9 points. The ABG showed an improvement with a pH of 7.31, PCO₂ of 24 mmHg, PO₂ 186 mmHg, and HCO₃⁻ of 11.7 mmol/L, with a Random Blood Glucose (RBG) of 9 mmol/L. On Day 14 a venous blood gas showed pH of 7.38, PCO₂ of 35 mmHg, HCO₃⁻ of 20.1, and the patient was successfully weaned off ventilation and extubated.

The following day the patient was fully conscious with GCS of 15 points, breathing spontaneously on room air; and an ABG revealed a pH of 7.45, PCO₂ of 34 mmHg, PO₂ of 83 mmHg, HCO₃⁻ of 22.9, and RBG of 5.8 mmol/L. A decision to discharge the patient from ICU but unfortunately on the second day after discharge from ICU, the patient was found dead on the medical inpatient ward.

Table No. 1

	Laboratory test result				
	On ICU admission	At 24 hrs	At 48 hrs	Day 6	Day 11
White blood cell (x10 ⁹ /L)[RV: 4.5- 10.5]	10.05	?	7.43	4.21	9.87
Hb (g/dl)[RV: 13.2 - 17.3]	13.1	13.9	12.9	10.7	9.4
Platelets (x10 ⁹ /L)[RV: 150 - 400]	67	?	61	89	244
pH	6.88	7.19	7.24	7.29	7.45
PCO ₂ (mmHg) [RV: 35 - 45]	13	32	32	33	27
PO ₂ (mmHg) [RV: 80 - 100]	119	60	82	125	118
HCO ₃ ⁻ [RV: 21 - 26]	?	11.7	13.5	15.4	18.2
Sodium (mmol/L)[RV: 133 - 145]	?	156	155	155	135
Potassium (mmol/L)[RV: 3.5 - 5.0]	3.9	5.2	4.6	3.8	3.4
Creatinine (µmol/L)[RV: 70- 123]	231	?	754.3	788	621
Urea (mmol/L)[RV: 2.5 - 7.1]	12.1	?	23	30.6	28.1
RBG (mmol/L)[RV: 7 - 11.1]	11.9	10.2	18.1	11.2	8.3

RV: Reference values; RBG: Random Blood Glucose; ?: No results available

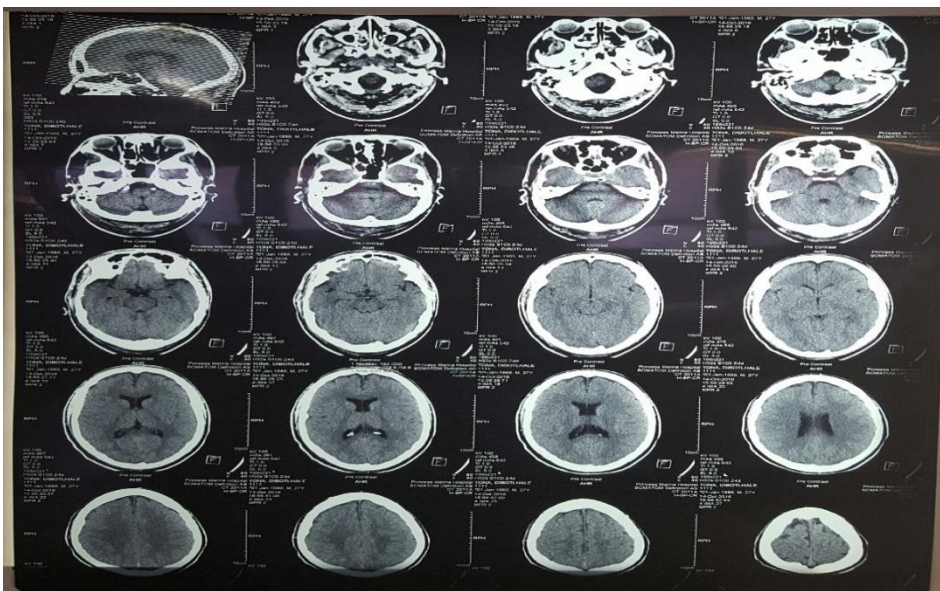


Figure 2: CT-head repeated 72 hours after sedation stopped due to poor level of consciousness which reveals cerebral edema

Discussion

Cerebral edema is a rare but severe complication of diabetic ketoacidosis (DKA), mainly seen in young children and adolescents, which may result in death.⁴ In adult cerebral edema during the course of DKA has been reported infrequently.^{4,7} In a study conducted in children with DKA, those with a higher serum urea nitrogen concentration and more severe hypercapnia at presentation were at increased risk for cerebral edema.⁵ This same study showed that a higher presenting serum sodium concentration [RR 0.8 (0.6 – 1.1); CI 95%; p=0.19] was also associated with greater likelihood of cerebral edema and the use of intravenous sodium bicarbonate was related with cerebral edema, associated with a RR of 0.8 (0.5–1.1); CI 95%; p=0.15 when the rate of increment was at 3 mmol/L/h compared to the cerebral edema group with a matched control group. A similar study reported an elevated initial BUN concentration (59.2%), more profound neurologic depression (95.2%) at the time of diagnosis of cerebral edema, and intubation with associated hyper-

ventilation to a PCO₂ level less than 22 mmHg (55.3%) were three variables associated with poor outcome in DKA-related cerebral edema.⁸ First presentation of diabetes has been associated with almost three times the risk of cerebral edema.⁹

In this case presentation, our patient was a first presentation of diabetes with a very high blood urea nitrogen level, mild hypernatremia, and severe hypocapnia (see table 1) found on admission to our ICU.

Intravenous sodium bicarbonate was administered several times in order to correct metabolic acidosis even when the pH was above 7.0.

It is possible that this high serum urea concentration reflects a severe dehydration state strengthening a possible pathophysiologic association between dehydration (and possible cerebral ischemia) and cerebral edema in the setting of DKA.⁸

Cerebral edema typically occurs 4 to 12 hours after treatment is initiated but can develop any time in treatment for DKA. Symptoms and signs of cerebral

edema are variable and include onset of headache, gradual decrease or deterioration in level of consciousness, inappropriate slowing of the pulse rate, and an increase in blood pressure.¹⁰

Neurological deterioration may occur rapidly with seizures, urinary incontinence, pupillary changes, bradycardia, and respiratory arrest as brain stem herniation and dysfunction occurs.

Papilledema may be absent if onset is rapid. Mortality rate has been reported as greater than 70% once neurological symptoms are established and only 7–14% of patients recover without sequelae.¹¹

CT-brain is a helpful diagnostic tool to diagnose this complication of DKA. Our patient remained in coma for several days even once sedation was ceased but gradually regained a normal level of consciousness allowing ventilator weaning.

Postulated mechanisms for cerebral edema include osmotically - driven movement of water into the central nervous system when plasma osmolality declines too rapidly during the treatment.^{5,6} This may happen because the neuron synthesized idiogenic osmolytes (e.g., glutamine, myoinositol and taurine) are reduced too quickly during treatment and the osmolality remains high inside the neuron which draws water into them.^{6,10} Another theory suggests that acidification of the cytosol

by organic ketoacids activates the plasma membrane Na⁺/H⁺ exchanger, increasing brain sodium and water.

Relative alkalization of the extracellular fluid due to insulin treatment would further promote Na⁺/H⁺ exchange, favouring sodium and water influx into brain.⁶

Treatment of cerebral edema in DKA should be initiated as soon as the condition is suspected. The rate of intravenous and oral fluid administration should be strictly monitored. Although mannitol has been shown to have possible beneficial effects in case reports;^{12,14} there has been no definite beneficial or detrimental effect in retrospective epidemiologic studies.¹⁰

The response may be altered by timing of administration, delayed administration being less effective. Mannitol should be given (0.25–1.0 gr/kg intravenously over 20 minutes) in patients with signs of cerebral edema before impending respiratory failure.

The dose may be repeated within 2 hours if there is no initial response.

Hypertonic saline 3% (5 to 10 mL/kg over 30 minute) may be an alternative to mannitol,¹⁰ but only in cases of known low sodium concentration.

Intubation and ventilation are often necessary; however aggressive hyperventilation has been associated with poor outcomes.⁸

Conclusions

In managing patients with DKA, aggressive intravenous fluid resuscitation in the early stages of severe dehydration; high urea concentration and first presentation diabetes are associated with a high risk of cerebral edema. It is not recommended to administer intravenous sodium bicarbonate to correct me-

tabolic acidosis until the pH falls below 7.0 as this is also associated with this rare but lethal complication of DKA.

All patients with DKA should have close monitoring of GCS, fluid balance and electrolytes with supervision by experienced medical staff.

Bibliographic references

1. Dillon ES, Riggs H, Dyer WW. Cerebral lesions in uncomplicated fatal diabetic acidosis. *The American Journal of the Medical Sciences*. 1936;192(3):360-5.
2. Levin DL. Cerebral edema in diabetic ketoacidosis. *Pediatric Critical Care Medicine*. 2008;9(3):320-9.
3. Kitabchi AE, Umpierrez GE, Miles JM, Fisher JN. Hyperglycemic crises in adult patients with diabetes. *Diabetes care*. 2009;32(7):1335-43.
4. Haringhuizen A, Tjan D, Grool A, Van Vugt R, Van Zante A. Fatal cerebral oedema in adult diabetic ketoacidosis. *Neth J Med*. 2010;68(1):35-7.
5. Glaser N, Barnett P, McCaslin I, Nelson D, Trainor J, Louie J, et al. Risk factors for cerebral edema in children with diabetic ketoacidosis. *New England Journal of Medicine*. 2001;344(4):264-9.
6. Silver SM, Clark EC, Schroeder BM, Sterns RH. Pathogenesis of cerebral edema after treatment of diabetic ketoacidosis. *Kidney international*. 1997;51(4):1237-44.
7. Troy PJ, Clark RP, Kakarala SG, Burns J, Silverman IE, Shore E. Cerebral edema during treatment of diabetic ketoacidosis in an adult with new onset diabetes. *Neurocritical care*. 2005;2(1):55-8.
8. Marcin JP, Glaser N, Barnett P, McCaslin I, Nelson D, Trainor J, et al. Factors associated with adverse outcomes in children with diabetic ketoacidosis-related cerebral edema. *The Journal of pediatrics*. 2002;141(6):793-7.
9. Edge J, Hawkins M, Winter D, Dunger D. The risk and outcome of cerebral oedema developing during diabetic ketoacidosis. *Archives of disease in childhood*. 2001;85(1):16-22.
10. Dunger DB, Sperling MA, Acerini CL, Bohn DJ, Daneman D, Danne TP, et al. European Society for Paediatric Endocrinology/Lawson Wilkins Pediatric Endocrine Society consensus statement on diabetic ketoacidosis in children and adolescents. *Pediatrics*. 2004;113(2):e133-e40.
11. Nyenwe EA, Kitabchi AE. The evolution of diabetic ketoacidosis: An update of its etiology, pathogenesis and management. *Metabolism*. 2016;65(4):507-21.
12. Franklin B, Liu J, Ginsberg-Fellner F. Cerebral edema and ophthalmoplegia reversed by mannitol in a new case of insulin-dependent diabetes mellitus. *Pediatrics*. 1982;69(1):87-90.
13. Shabbir N, Oberfield SE, Corrales R, Kairam R, Levine LS. Recovery from symptomatic brain swelling in diabetic ketoacidosis. *Clinical pediatrics*. 1992;31(9):570-3.
14. Roberts MD, Slover RH, Chase HP. Diabetic ketoacidosis with intracerebral complications. *Pediatric diabetes*. 2001;2(3):109-14.

¹Department of Emergency Medicine, Faculty of Medicine, University of Botswana

²Princess Marina Hospital, Intensive Care Unit, Gaborone, Botswana

³Department of Internal Medicine, Faculty of Medicine, University of Botswana

Conflict of interest: None

Received: January, 24th, 2017

Approved: March, 13th, 2017

Alexei Ortiz Milan. Faculty of Medicine, University of Botswana, Botswana. Tel: +267 3555515 E-mail: aortizmilan@gmail.com
